

CHIRURGEON'S BURDEN

NEWSLETTER FOR AN TIR CHIRURGEONS

ISSUE #9 – January, 2006

Editor: Lianna Stewart, MC, GdS

Your Kingdom Chirurgeon Speaks!




Greetings, all!

Fortieth Year is coming up quickly, and our planning moving along to meet it. We have the honor of hosting the Society Chirurgeon and the Known World Chirurgeons Symposium, and a lot of good folks are coming to learn and work with us. The symposium fee is \$35. All the fees come to us and go in a lump with the list to the site owner and Gate folks. You will be signing waivers at the gates, and they'll check you off their list of symposium attendees. Please note the plural - you will be approached by two people when you get to gate - one from the event and one from Camel-Lot, the site owner. Symposium is the first weekend, and only those on the symposium list get that fee first weekend. The second weekend is a lower rate for everyone - and trust me, we'll need the help of chirurgeons coming in the second weekend to handle both the larger numbers and the fact that the folks who've been at it all week will be tired.

In service to you, our Crown, and the Dream,

THLord Tvorimir Danilov, MC, GdS, JdL, WOAW
Kingdom Chirurgeon, An Tir




THE CHIRURGEON

By Lianna Stewart, MC, GdS

A chirurgeon is a person who volunteers their time at an event to provide first aid. The chirurgeonate is the group of chirurgeons. According to SCA rules and regulations it is not mandatory to have a chirurgeon present to hold a sanctioned event. Those who volunteer provide first aid to anyone requesting their services or initiate the referral process to send the person whose needs are above the first aid level to medical providers.

Anyone who wishes can be a chirurgeon. The minimum requirements are that the volunteer must have completed a CPR/1st aid class, be 18 years old or older, have membership in the SCA, and have filled out an application. The application can be gotten from a chirurgeon or on the Kingdom Chirurgeon's website. One such location is: <http://www.chirurgeon.wastekeep.org> Such regulating bodies as the American Heart Association, the American Red Cross, St. John's Ambulance (for Canadians), and many others provide certification in CPR/1st Aid. A copy of your CPR card, your membership card, and proof of age must accompany the application. Some chirurgeons have higher certifications (i.e.: EMT, RN, MD, military medic and more,) but, when acting as a chirurgeon, only first aid is practiced. Any additional services provided by those higher certified must be done under their personal licenses/certifications and not as a chirurgeon.

The chirurgeonate has a structure headed by the Society Chirurgeon, affectionately known as the chirurgeon general. This is a society level officer who reports to the Board of Directors. In line under this officer are Kingdom Chirurgeons who report to this person and to their respective Kings. Each Kingdom has a Kingdom Chirurgeon. Initially, each person joining the chirurgeonate is considered an "apprentice" chirurgeon. Regardless of the person's level of training in healthcare, all new chirurgeons are supervised by more experienced chirurgeons called "journeyman" chirurgeons. This supervised period, which can be as little as three events, helps the new chirurgeon to know how to do the paperwork and gives the journeyman a chance to be certain the first aid skills are minimally present. The chirurgeonate also has a title of respect, "master" for those chirurgeons whom their KC had determined to have been a knowledgeable, experienced, hard-working resource and mentor for other chirurgeons. The "master" has neither authority nor extra



CHIRURGEON'S BURDEN

NEWSLETTER FOR AN TIR CHIRURGEONS

ISSUE #9 – January, 2006

Editor: Lianna Stewart, MC, GdS

medical training, but has simply earned recognition above and beyond. This “masters” honor confers no rank or privilege on the owner. Lastly, the chirurgeonate recognizes their chirurgeons who can no longer perform first aid, but who wish to be available as resources, by the title “Emeritus.”

Chirurgeon's can be recognized by their red baldrics which have on them a badge of a fleam (it looks like an upside-down two) in white. The apprentices have no border on their baldrics, the journeyman wears a silver or white edging, and honorific masters wear gold. A banner in red with a white fleam will announce a “point” which would be similar to a first aid station. Points will be located at events near the battle field or close to the camping area in an easily reached area.

Anyone wishing to learn more specifics about chirurgeons should read “The Chirurgeon’s Handbook which can be accessed at the above website or at www.chirurgeon.net. It is approved by the Board of Directors and updated periodically by the Society Chirurgeon.

Chirurgeon’s Spotlight

A new feature of the newsletter is introducing one of the chirurgeons presently working in our world. The following is about Aaron whom I hope you will have a chance to meet and work with in the future:

Companion Aaron of the Black Mountains



Order of Hospitaliers of Saint John of Jerusalem
Brother at Office & Brother at Arms. Circa 1220 AD

Awards


Order of the Pelican
Award of Arms (Middle)
Goutte de Sang
Jambe de Lion
Iron Chain
Lion's Claw (Lions Gate)
Master Chirurgeon
Order of the Pernicious Lily
Baroness' Champion of Science (Lions Gate)
Magistrae Ithra
Lector Scientae
Scroll of Honor (Ealdormere)

OP, AoA, GdS, JdL, IC, LC, MC, OPL, MI, LS, SoH

Offices Held in the Past

Barony of Lions Gate Chirurgeon (Three different times)
Northern Regional Chirurgeon (October 26, 1997 - May 20, 2003)
Northern Guild Master, Armorers Guild Unofficial Obituary Clerk for the An Tir Senior Teaching Marshall (Heavy)

Aaron has been a bulwark for the chirurgeonate in northern An Tir. He can be counted on to provide support and direction to any chirurgeon. If you have a chance (and, I hope I soon can meet this wonderful chirurgeon) work with him. You will learn.



CHIRURGEON'S BURDEN

NEWSLETTER FOR AN TIR CHIRURGEONS

ISSUE #9 – January, 2006

Editor: Lianna Stewart, MC, GdS

If I were talking to a new chirurgeon what would I tell them?


By Lianna Stewart, MC, GdS

- Please have fun! If it's not fun, why do it?
- Ask either at gate or after you've set up camp where to find the chirurgeon-in-charge or point.
- What do you know about the job of chirurgeon?
- What questions would you like to ask?
- Have you had a chance to read "The Chirurgeon's Handbook"?
- Do you have any questions over anything in the handbook?
- Most of the first aid required of a chirurgeon is simple We learn how to apply band aids wearing gloves (which is fun because they stick).
- WEAR GLOVES! You are touching someone else. They are used to their germs/microorganisms, you aren't. Let them keep them.
- Always bring an extra garbage bag for disposables to chi point—everyone else forgets.
- Remember—here you do first aid; anything else is off-baldric and, most likely, you're only keeping them going while 9-1-1 shows up.
- If someone needs first aid attention which is beyond simple and you feel it's out of your scope-of-practice, call 9-1-1.
- Most of what we do is simple.
- Bring something to do or someone to talk with. A good event = a bored chirurgeon.
- Take care of yourself—you are no good to anyone if you become a victim.
- Take care of yourself:
- Arrange for shade, sunscreen, a hat, adequate water/hydration, a meal break, bring snacks, a chair (who wants to stand all day/night). If a meal break isn't possible, arrange for a meal to be brought to you. Warm/cool food/drinks are wonderful when the weather is cold/rainy/snowy/hot.
- Shelter is good—bring your own or ask permission to share.
- Ask questions—sometimes the "old farts" forget the questions they had at first.
- There are no stupid questions.
- If you're overwhelmed, you're overwhelmed. Get help even if you have to call 9-1-1. Nobody created you god/ess.
- Always thank your helpers.
- Work with the waterbearers. They save you lots of work.
- Work with your marshals. Don't enter a war field without permission.

And, from Aaron:

- Relax, have fun!
- Newcomers, do not worry about the old timers, just do your best, hang out, jump in and soon you'll be one of those "old-timers" too.
- Old timers, cut the newcomers lots of slack, encourage as much as possible, tell lots of "war"/No s**t" stories as possible. Remember that folks can learn from our experiences if we're honest.
- Above all remember that your there to have fun!!!!

I know there are lot's more things to tell/ask newbies. Any one with suggestions?



CHIRURGEON'S BURDEN

NEWSLETTER FOR AN TIR CHIRURGEONS

ISSUE #9 – January, 2006

Editor: Lianna Stewart, MC, GdS

There has recently been much discussion on the SCA-Chirurgeon's mailing list in regards to spider bites. Specifically, the brown recluse spider or the fiddleback spider was discussed. A request was put out on the list for someone to write an article on spider bites. At about the same time, an article appeared in our company newsletter about a co-worker who had recently been hospitalized by a spider bite in Phoenix, Arizona. This, combined with the earlier discussions on the Chirurgeon's list, sparked my interest to the point that I began doing some further research into spider bites and found a wealth of information about spiders and their bites. This article is the result of that research.

Due to considerations of scope and length I have specifically limited this articles to the spiders considered clinically significant within the United States.

Lord Conal Mac Nachitan,
Journeyman Chirurgeon.
February 27, 2006,

All Stings Considered...


Of the more than 3,000 kinds of spiders in the United States, only about 60 species have been implicated as causing medically significant bites to people. Many spiders are not capable of breaking the skin with their fangs while other species contain venom that causes no reaction. Spiders are usually very timid and will only bite in self-defense if mishandled, cornered, or injured. Even when they bite, spiders do not always inject venom. The severity of the reaction to a spider bite will differ among individuals. Most spider bites are less painful than a bee sting. Research has shown that approximately 80% of suspected spider bites are caused by other arthropods, such as insects and ticks, or other disease states. Conversely, a large number of spider bites are misdiagnosed when first evaluated.

Spider bites are placed into three separate categories; possible, probable, and proven. A *Possible* spider bite is one which the physician feels *could* be a bite by a spider, but lack sufficient clinical or circumstantial evidence to support a firm diagnosis. A *Probable* spider bite is one in which the clinical and/or circumstantial evidence support the likelihood of spider bite, but the biting spider was not recovered and positively identified. A *Proven* spider bite applies to those cases in which the clinical and circumstantial evidence support the diagnosis of spider bite, and *the* biting spider was captured and positively identified.

Most spider bites are single, not in rows or patches like those of some parasitic arthropods (such as bed bugs, biting midges, black flies, fleas and mosquitoes); multiple bites do occasionally occur, such as when the spider is trapped between skin and clothing and cannot escape. Actual spider bites show two puncture marks although the wound is not always obvious. A rather typical reaction may involve localized reddening and various degrees of swelling, itching, and pain. Within a few hours a small red, blue, or black discoloration can develop around the bite site. The area may remain tender for a few days, and eventually a small sore can develop that soon begins healing.

Clinically Significant Spiders

Unfortunately, not all spider bites are as mild and fast healing as the typical bite. There are four types of spiders in the United States that are considered to be clinically significant. These are the Black Widow, The Brown Recluse (and other Specie of Recluse), several species of the Yellow Sac Spider, and the Hobo Spider.



CHIRURGEON'S BURDEN

NEWSLETTER FOR AN TIR CHIRURGEONS

ISSUE #9 – January, 2006

Editor: Lianna Stewart, MC, GdS

The major differences in the symptoms and treatment of bites from these spiders deal with the type of venom the spider injects. Spider venom, like snakebite venom, is generally either neurotoxic or cytotoxic. In spiders it is typically the web dwellers that have neurotoxic venom and the non-web dwellers have the cytotoxic venom.

Neurotoxic venom affects the neuromuscular junctions. There is usually a sharp, burning pain at the site, spreading to the lymph nodes within 15 minutes. Severe muscle pain and cramps typically develop within an hour, resulting in tightness in the chest and difficulty in walking. Additional symptoms may include anxiety, raised blood pressure, breathing difficulties and heart palpitations, nausea and vomiting, sweating, excessive salivation and watery eyes. The body temperature could either fall or rise above normal and the blood pressure may rise with an increased pulse rate. A rash might develop

The only spiders in the group we are discussing with neurotoxic venom are the Widow spiders of the *Latrodectus* family, of which three common species (Black Widows) and two lesser known species (Red and Brown Widows) exist in the United States. Less than 5% of untreated cases result in death, usually as a result of respiratory failure. Those more severely affected are children (smaller blood volume) and the elderly who might suffer respiratory or heart failure.

Cytotoxic venom affects the cellular tissue and is usually restricted to the area of the bite but can spread. The bite is at first painless with symptoms developing about 2-8 hours after the bite. Typical symptoms may include the development of an open ulcerating lesion, with the associated classical “Bulls-eye” pattern within two to three days. This lesion may take as long as three to six weeks to completely heal.

Of the spiders we are discussing, those with cytotoxic venom include the Recluse family, the Yellow Sac family, and the Hobo Spider. Bites from these spiders with cytotoxic venom are often referred to as *necrotic arachnidism* or *necrotic envenomation*, a term meaning "spider bite which causes tissue death." Death from a bite of these spiders is extremely rare; only two reports have been documented, both from probable, not proven recluse bites.

Identifying the culprit


It is to our best interest to make ourselves aware of the spiders that may be indigenous to our local area so that we can be aware of the signs and symptoms to look for when a patient may approach us with a suspected or proven spider bite. Being aware of the spiders' preferred nesting areas and habits will allow us to warn others to their possible presence, and hopefully prevent a bite.

The Widow Spiders



The widow spiders, genus *Latrodectus*, are among the most recognized spiders on earth; they are the largest of the cobweb weavers, family *Theridiidae*, and all species are poisonous. The term *widow* spider originated from the idea that the females devour the males after, or during, mating. This mate devouring behavior is somewhat a myth; while it may occur in captive situations, where the male cannot escape, it is uncommon in the field.

Black Widow spiders inhabit most warmer regions of the world to latitudes of about 45° north and south. They can be found on the underside of rocks and ledges, in plants, debris piles, woodpiles, etc. Widow spiders build strong, sloppy webs, in which the females usually remain, hanging upside down most of the time. Female widow spiders are bulbous and shiny in appearance, and may have bodies 12-16 mm long. Males are much smaller than the females, with longer legs; they are so different in appearance than females, that they are rarely recognized as widow spiders by the lay person. Males are not considered a threat to humans, although they do



CHIRURGEON'S BURDEN

NEWSLETTER FOR AN TIR CHIRURGEONS

ISSUE #9 – January, 2006

Editor: Lianna Stewart, MC, GdS

possess venom and can bite. Juvenile widow spiders are usually light colored, and darken to their adult coloration gradually, with each successive molt of their exoskeleton.

The term **black widow** refers to those species in the United States, Europe, and some other areas, which are shiny black in appearance. The most well known of the U.S. black widows is the southern widow, *Latrodectus mactans*, whose Latin name translates "murderous biting robber." The southern widow is found in the southeastern U.S., west to central Texas and Oklahoma, and north to southern New York; it is also found in the West Indies. Like most widow spiders, it prefers dark, cool places to build its web, such as outhouses, window wells, under well covers, and beneath trash. The red "hourglass" of the southern widow is actually shaped more like an *anvil* than a perfect hourglass in most specimens. The southern widow causes many envenomations in humans, particularly in the southern part of its range, where it is most common.

The western black widow, *Latrodectus hesperus* (photograph), ranges from extreme southwestern Canada, south into Mexico, and east to west Texas. *Hesperus* is the common black widow of the western United States, and is abundant in regions of Arizona, California, and other westerly locales. One of its favored natural habitats is in abandoned rodent holes, but it is often found around human habitations, even in the "downtown" districts of many western U.S. cities. The western widows' general appearance is very similar to that of the southern widow; the "hourglass" marking in the western widow is usually shaped like a perfect hourglass, though it is divided into two separate "spots" in some specimens. Like its southern cousin, the western widow causes a large number of bites, particularly in the southern part of its range.

The northern widow, *Latrodectus variolus*, is the third *black widow* found in the United States. It is found from extreme southeastern Canada, throughout the New England states, and south to northern Florida. It prefers undisturbed wooded areas, stone walls, stumps, and similar habitats. The "hourglass" of the northern widow is usually divided into two separate, elongate markings. This species is most common in the northern part of its range. While its venom is very similar to that of the southern and western widows, and bites do occur, it does not appear to bite humans as often as those species.

The red widow, *Latrodectus bishopi*, is a U.S. species with a restricted range, being found only in palmetto fronds of sandy, scrub-pine regions of central and southern Florida. This spider is rather brightly colored, with red legs and cephalothorax (fore-part of the body), and a black abdomen with orange and white markings down the back and sides. The "hourglass" usually consists a single red elongate marking. Little is known of the bite of the red widow, but its venom is probably quite toxic to mammals.


The brown widow, *Latrodectus geometricus*, is a cosmopolitan species, found in most tropical seaports around the world; it is an introduced species in Florida. Coloration may vary, but is usually brown to gray, with white and black markings on the back and sides of the dorsal abdomen. The "hourglass" is usually complete. This species is often found on or around human habitations and other buildings. While definitely venomous to humans, bites tend to be less severe than those of most other widow spiders.

The Recluse Spiders



Of the spiders listed, the Brown Recluse or *Loxosceles reclusa*, is the most commonly known. The brown recluse spider belongs to the genus *Loxosceles*, a unique family of arachnids known as the *Sicariidae*, or *six-eyed sicariid spiders*. The sicariids have six (rather than the typical eight) eyes, which are arranged in a horseshoe pattern in three clusters of two eyes each. The family consists not only of the recluse spiders, but also of the six-eyed crab spiders, genus *Sicarius*, of Central and South America, and South Africa.

In the United States there are eleven indigenous species of recluse spider, and two species introduced from other countries. The most noted of these is the brown recluse. The brown recluse is found in the Midwest and parts of the south; it ranges (see map) from southern Wisconsin east to Ohio, and south to extreme northern Florida and



CHIRURGEON'S BURDEN

NEWSLETTER FOR AN TIR CHIRURGEONS

ISSUE #9 – January, 2006

Editor: Lianna Stewart, MC, GdS

central Texas. The adult brown recluse has a body length of 10-12 mm (0.4 to 0.5 inches.) This species is also frequently called the "fiddleback" or "violin" spider, due the violin-like marking on the dorsal cephalothorax. The apparent presence of a violin-like marking on the cephalothorax or elsewhere is not sufficient to identify a spider as belonging to the recluse group. Many other spiders have markings which somewhat resemble "violins". The brown recluse became the first U.S. spider associated with necrotic arachnidism in 1957, when it was linked to severe bites in the Midwest. All recluse spiders, as well as the six-eyed crab spiders, are now considered venomous to humans.

The other ten recluse species which are indigenous or have been imported to the United States range throughout the lower southwest, from southern California through southern Texas. These other recluse spiders are:


- The **Apache recluse**, *Loxosceles apachea*: Ranges from southeastern Arizona, through southern New Mexico, to extreme western Texas.
- The **Arizona recluse**, *Loxosceles arizonica*: Found in central and southern Arizona, and southeastern California.
- The **Baja recluse**, *Loxosceles palma*: Found in southern California, and northern Baja, Mexico.
- The **Big Bend recluse**, *Loxosceles blanda*: Western Texas.
- The **Chilean recluse**, *Loxosceles laeta*: **Introduced** from South America, colonies exist in southern California. A large (25 mm) spider, with a particularly severe bite.
- The **desert recluse**, *Loxosceles deserta*: A pale colored species which ranges from south-central to southern California, east to south-central Arizona, and north to southern Nevada and the Saint George, Utah area.
- The **Grand Canyon recluse**, *Loxosceles kaiba*: Grand Canyon area, Arizona.
- **Martha's recluse**, *Loxosceles martha*: Southern California.
- The **Mediterranean recluse**, *Loxosceles rufescens*: An **introduced** species from the Mediterranean region, which has been found in various cities across the U.S. Its bite is not regarded as being as severe as some of the other spiders of this genus.
- **Russell's recluse**, *Loxosceles russelli*: Found in the Death Valley area of southern California.
- The **Texas recluse**, *Loxosceles devia*: Southern Texas.
- The **Tucson recluse**, *Loxosceles sabina*: The Tucson area of southern Arizona.

These other recluse spiders look very much like the brown recluse, and can be positively distinguished only by an expert. The key in identifying these types of recluse spiders will lie in the geographic area in which the spider is found or the bite occurs.

The Yellow Sac Spiders



The yellow (golden) sac spiders, genus *Cheiracanthium* are members of the spider family *Clubionidae* (sac spiders): Members of this family build a sack-like, silken tube in foliage or under bark or stones as their lair. There are two species documented to be of clinically significant, *Cheiracanthium inclusum* and *Cheiracanthium mildei*. Yellow Sac spiders can be found walking about on foliage; under leaf litter, stones, and boards; and on buildings under the window sills and siding, in addition to the corners of walls and ceilings within homes. They probably account for more spider bites than any other spider, and their bites are sometimes misdiagnosed as brown recluse bites by health care providers. *C. inclusum* is indigenous to much of the United States (except the northernmost states), while *C. mildei*, an introduced species from Europe, was found throughout much of the Northeast as of 1978. It is likely that *C. mildei* has substantially increased its range since that time. These spiders are relatively small (10 mm body length), and are yellowish in color; they are difficult to distinguish from one another, and species identification requires examination by an arachnologist.



CHIRURGEON'S BURDEN

NEWSLETTER FOR AN TIR CHIRURGEONS

ISSUE #9 – January, 2006

Editor: Lianna Stewart, MC, GdS

The Yellow Sac spider was first identified as a cause of necrotic arachnidism in 1970, when it was linked with skin lesions in the Boston, Massachusetts area (where it is the most common spider found in houses); it is also common in houses in New York City. In the late 1970's and early 1980's the Yellow Sac spider produced a significant number of bites in the Provo, Utah area, and has been reported responsible for bites in Georgia and southwestern Canada; bites by this species are probably far more common and widespread than this, and it is likely that more reports will surface as the Yellow Sac spider becomes better known as a clinically significant spider.

Yellow sac spiders are among the least known clinically significant spiders, but they are indeed capable of causing a painful bite with development of a necrotic lesion (not as severe as the brown recluse or hobo), and can sometimes produce systemic effects as well. They are very prone to bite defensively (more so than any other significantly venomous U.S. spider.) Some bites in humans have occurred in unusual places, such as in automobiles and swimming pools. The bite of *C. inclusum* is more destructive than the bite of *C. mildei*. Humans usually incur *C. inclusum* bites outdoors while gardening in the summer. *C. mildei* will readily bite, despite their small size, and they have been observed crawling across the human skin surface and biting without provocation. It is likely that many cases of necrotic arachnidism ascribed to the brown recluse spider outside of its natural range are actually Yellow Sac spider bites.

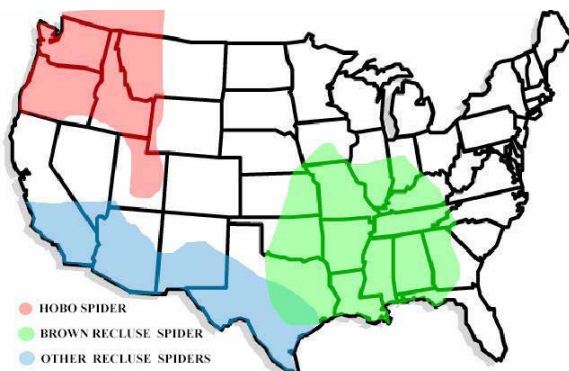
The Hobo Spider



The hobo spider is a moderately large spider of the family Agelenidae which was originally indigenous to Western Europe. The Hobo spider was most likely introduced into the northwestern United States through the port of Seattle sometime before the 1930's. They are brown and measure roughly 10-15 mm (0.4 - 0.6 inches) in body length and 15 to 45 mm (0.6 - 1.8 inches) in leg span. Their legs show no distinct rings and have short hairs. Their abdomens have several chevron shaped markings. Males are distinctively different from females in that they have two large palpi (mouth parts) that look like boxing gloves. These palpi are often mistaken for fangs or venom sacs, but they are in fact the male genitalia. The females also have these palpi, but the ends are not enlarged as they are in the males. Females tend to have a larger and rounder abdomen when compared to males.


The Hobo spider has a distinctive web that is horizontal and flat with a funnel at one end. These funnel shaped webs are often attached to an object in the yard, by the foundation of structures, or anything that remains stationary near the ground. The spiders rarely climb vertical surfaces and are uncommon above basements or ground level.

Ranges of Spiders known to inflict Necrotic Envenomation



Each of the spiders documented to inflict necrotic envenomation, the Recluse spiders, The Yellow Sac spiders, and the Hobo spider has a specific range in which it lives. These ranges are defined by many factors, including, but not limited to the spiders' mobility, the presence of predatory species outside its known range, and its climatic adaptability:

It becomes obvious when looking at the ranges of the various spiders that many of the spider bites reported in the media as having been inflicted by a Brown Recluse occurred well outside the known range of that spider. While each of the spiders discussed in this article can produce a necrotic lesion as one of its symptoms, the systemic effects of the bites of these various spiders differ, and may be treated in different ways. Knowledge of the ranges of these spiders can



CHIRURGEON'S BURDEN

NEWSLETTER FOR AN TÍR CHIRURGEONS

ISSUE #9 – January, 2006

Editor: Lianna Stewart, MC, GdS

help prevent the misdiagnoses of the type of bite, and can be essential in helping the victim of a spider bite receive the best possible care.

Signs and Symptoms

Spider venom poisoning is characterized by a set of **signs** (observable physical or objective evidence of disease) and **symptoms** (complaints that the bite victim relays to the physician, etc.), which lead to the diagnosis of spider envenomation.


When envenomation does occur from the bite of a spider, *local* and/or *systemic* manifestations may appear. The severity of these phenomena is dependent on the type of spider, and in the case of the hobo spider, on the age and sex of the biting spider. For example, in laboratory experiments the venom of the male hobo spider produces more severe effects than that of the female, and evidence exists suggesting that the venom of sub-adults may be more toxic than that of adults.

Bites by widow spiders often are initially painful, but sometimes are not felt. The local dermal reaction is minimal, usually consisting of little more than an area of *erythema* (redness) around the bite site, which disappears within several hours; no tissue necrosis occurs following bites by widow spiders. A potent neurotoxin in the venom induces the disease state *latrodectism*, which manifests itself with severe muscle cramping and spasms; the cramping usually begins in the large muscle masses of the legs, or the abdomen. The abdomen can exhibit a board-like rigidity, and the pain has been compared to that of acute appendicitis, and to childbirth. Some widow bite victims experience anxiety, profuse sweating, nausea, piloerection (hair standing on end), increased blood pressure, and other unpleasant manifestations. Paralysis, stupor and convulsions, as well as psychological abnormalities may occur in severe cases. Death can occur in a small percentage of cases, particularly when the victim is a small child or elderly person.

In envenomation by Hobo and Recluse spiders, a large (several cm.) area of redness (*erythema*) forms around the bite site: This *usually* disappears within a few hours, leaving a small reddish *induration* (hardened area), which is not dissimilar to the classical "mosquito bite". Within 24 to 48 hours blistering may occur at the bite site. Within an additional 24 hours these blisters may rupture, leaving an open ulceration. Within a few days of ulceration, if left uncovered, *eschar* or "scab" formation begins to develop over the lesion, and by three weeks post-bite this becomes pronounced, giving the lesion a "target and bulls-eye" appearance. Following this, the "scab" is sloughed and the lesion generally heals, leaving a scar, within 45 days of the original bite. In some instances, particularly when the bite is delivered in an area of fatty tissue, such local lesions may become deep and extensive, and may not heal for two to three years.

Systemic or generalized effects are seen in about 45% of people envenomated by Hobo spiders. The most common reported symptom is severe headache, which usually does not respond to over the counter analgesics (aspirin, which can prolong bleeding time, should not be used for hobo spider bite induced headaches.) In addition to this, victims may experience a dry mouth, nausea, weakness and lethargy, dizziness, visual disturbances, hallucinations, joint pain and/or other undesirable effects. As with many types of complex poisoning, most victims of systemic tegeranism do not experience all of these phenomenon, but that is dependent upon the severity of the poisoning. About 15% of envenomated subjects are poisoned severely enough to require hospitalization. In rare cases *aplastic anemia* (bone marrow failure) can develop several weeks after the bite, which results in a fatal outcome. Another rare but dangerous condition that has been seen following hobo spider envenomation is the development of severe intractable vomiting accompanied by secretory diarrhea.

The *systemic* effects of brown recluse spider bite (which occur in a small percentage of cases) differ somewhat from those of the hobo; chills, fever, nausea, muscle pain, and other flu-like symptoms can develop. In severe cases convulsions may occur, as well as abnormalities in the clotting ability of the blood. *Hemolysis*, or damage to red blood cell walls resulting in leakage of the red, oxygen carrying protein *hemoglobin* occurs in some cases; this can result in the death of the victim when the discarded red blood cell casts are filtered through the kidneys, causing renal failure. *Systemic poisoning effects from the other various members of the genus Loxosceles may vary from species to species. Little is known about the venom and bite of the lesser known species of recluse spiders*



CHIRURGEON'S BURDEN

NEWSLETTER FOR AN TIR CHIRURGEONS

ISSUE #9 – January, 2006

Editor: Lianna Stewart, MC, GdS

Bites by Yellow Sac spiders generally produce instant, intense stinging pain, not unlike that of the sting of a wasp or hornet. This may be followed by localized redness, swelling and itching; these manifestations may or may not evolve into a necrotic lesion, but when that occurs healing is usually complete within eight weeks. Systemic effects are *usually* not severe, but when they occur may include chills, fever, headache, dizziness, nausea, anorexia, and sometimes shock. Treatment for the local lesion should follow the same protocols as outlined for the hobo and brown recluse spiders.

What to do when someone is bitten

Reassure the Patient: Most bites initially self identified as “spider bites” eventually turn out to be bites by parasitic arthropods such as bed bugs, biting midges, black flies, fleas and mosquitoes. These types of bites are typically in patches, rows or groups. Spiders, on the other hand, tend to bite once, unless trapped by clothing. While a spider bite should not be ruled out based on this, particularly in light of other clinical evidence, informing a patient of this information can help relieve some of the psychological phobias associated with spider bites. Most spider bites are no more painful than a bee sting, and if not accompanied by an allergic reaction to the venom, require little more first aid.


Gather evidence: If possible, if someone is bitten by *any* spider, and they actually catch *the* spider in the act, *always* capture the spider for identification by a qualified arachnologist. *Never* discard a spider that has definitely bitten a human. In the case of the hobo spider, not only is positive species identification important, but so is a determination of the spiders sex and age; these factors can help predict the severity of potential poisoning, and assist the attending physician in charting a course of treatment. Preserve the spider (or whatever parts of it remain) and send it to the clinic with the patient.

Provide effective First Aid: For our part, our treatment of any type of spider bite, be it clinically significant or not, will be virtually unchanged. Typical first aid for a spider bite includes:

- Cleaning the site well with soap and water.
- Applying a cool compress over the bite location.
- OTC medications such as acetaminophen or ibuprofen (if requested and self administered) may be effective to relieve minor signs and symptoms in adults.
- Be observant for any signs of an allergic reaction to the bite. This can occur from the bite of any type of spider, clinically significant or not.
- Treatment in a medical facility may be necessary for children less than 6 years old and for adults with severe signs and symptoms.

Clinically, for most spider bites, no further first aid is typically required. However, it would be prudent to advise a patient that they should seek medical attention. If a patient has been bitten by, or thinks that they have been bitten by a spider of clinical significance rapid and proper treatment is essential:

- The most recommended treatment for venomous spider bites is referred to as the RICE method: Rest, Ice, Compress, and Elevate.
 - **Rest:** Keep the patient or the affected part as motionless as possible.
 - **Ice:** Apply crushed ice to the affected area. The cold helps to retard the venom action and reduces pain. This must be done within minutes of being bitten. Do not cool for an extended period and remove periodically for the feeling to return otherwise tissue damage might result.
 - **Compress:** Apply a compression bandage, winding towards the bite to retard the spread of the venom.
 - **Elevate:** Elevate the affected area.
- Eating, drinking and smoking should be avoided.
- Strongly recommend medical assistance.



CHIRURGEON'S BURDEN

NEWSLETTER FOR AN TIR CHIRURGEONS

ISSUE #9 – January, 2006

Editor: Lianna Stewart, MC, GdS

Calming and reassuring the patient is an important part of initial and continuing care. Some important information that can be conveyed to a patient includes the following:

- Necrotic arachnidism does not invariably develop following a bite by a Recluse, Hobo, or Yellow Sac spider. A large percentage (perhaps 50% or more) of defensive bites by spiders are "dry", and no venom is injected when the spider bites. Spiders, like many other venomous creatures, are more likely to incorporate venom in a *food getting* bite than in a defensive bite.
- While extremely painful, the bite of one of the Widow spiders is seldom fatal. While this may not be reassuring to a patient in pain, it can be very reassuring to friends and family.

Bibliography

- Meier, J, and White J. (1995) *Handbook of Clinical Toxicology of Animal Venoms and Poisons*. CRC Press, Boca Raton.
- Blackman, J.R. (1995): Spider Bites. *Journal of the American Board of Family Practice*. 8(4), pp. 288-294 (July).
- Atlas, E. and Yee, A. (2005) Bites of the Brown Recluse Spider. *New England Journal of Medicine*. 352:2029-2030, pp. 19
- Breene, R.G. (1997): Recluse spiders and the hobo spider in North America. *American Tarantula Society manual*.
- Taylor EH, Denny WF. (1966) Hemolysis, renal failure and death, presumed secondary to bite of brown recluse spider. *Southern Medical Journal* 1966;59:1209-11.
- Chu JY, Rush CT, O'Connor DM. (1978) Hemolytic anemia following brown spider (*Loxosceles reclusa*) bite. *Clinical Toxicology* 1978;12:531-4.
- Fisher, R.G., Kelly, P., Krober, M.S., Weir, M.R. and Jones, R. (1994): Necrotic Arachnidism. *Western Journal of Medicine*. (160)6, pp. 570-572.
- Web Site: Commonly Encountered Pennsylvania Spiders. *Penn State College of Agricultural Sciences. Entomological Notes*. <http://www.ento.psu.edu/extension/factsheets/Spider/spiders.htm>
- Vest, D.K., Keene, W.E., Heumann, M. and Kaufman, S. (1996): Necrotic arachnidism -- Pacific Northwest, 1988-1996. *Morbidity and Mortality Weekly Report*. 45(21), pp. 433-436. Centers for Disease Control and Prevention (Atlanta, Georgia, U.S.A.), May 31, 1996.
- Baldwin, G.A., Smith, D.F. and Fike, S.D. (1988): Loxoscelism in Canada.
- Vest, D.K. (1987): Necrotic arachnidism in the northwest United States and its probable relationship to *Tegenaria agrestis* (Walckenaer) spiders. *Toxicon*. 25(2), pp. 175-184.